ELSEVIER

European Journal of Cardio-thoracic Surgery 20 (2001) 502–507

EUROPEAN JOURNAL OF CARDIO-THORACIC SURGERY

www.elsevier.com/locate/ejcts

Effects of cryoanalgesia on post-thoracotomy pain and on the structure of intercostal nerves: a human prospective randomized trial and a histological study ☆

Narain Moorjani[a], Fengrui Zhao[b], Yanchu Tian[b], Chaoyang Liang[b], Joseph Kaluba[c], M. Omar Maiwand[a,*]

[a]*Department of Cryoresearch, Harefield Hospital, Harefield, Middlesex UB9 6JH, UK*
[b]*Department of Thoracic Surgery, China-Japan Friendship Hospital, Beijing, China*
[c]*Department of Histopathology, Barnet General Hospital, London, UK*

Received 11 October 2000; received in revised form 4 May 2001; accepted 18 May 2001

Abstract

Objective: The choice of analgesia in the management of post-thoracotomy pain remains controversial. Although several alternative forms of post-thoracotomy analgesia exist, all have their disadvantages. Cryoanalgesia, localized freezing of intercostal nerves, has been reported to have variable effectiveness and an incidence of long-term cutaneous sensory changes. We carried out an animal study to assess the reversibility of histological changes induced by cryoanalgesia and a prospective randomized trial to compare the effectiveness of cryoanalgesia with conventional analgesia (parenteral opiates). **Methods**: In six anaesthetized dogs, intercostal nerves were exposed to a varying duration of cryo-application (30, 60, 90 and 120 s). The nerves were biopsied and examined histologically at regular intervals over the following 6 months. In the clinical study, 200 consecutive patients undergoing thoracotomy were randomized to cryoanalgesia and conventional (parenteral opiates) analgesia groups. Postoperative pain scores, respiratory function tests and use of opiate analgesia were measured for the two groups. **Results**: Following application of the cryoprobe, degeneration and fragmentation of the axons was evident with associated inflammatory changes. As the endoneurium remained intact, axonal regeneration took place after the resolution of axonal swelling. Over the course of weeks, recovery of the intercostal nerve occurred and was complete after 1 month for the 30 and 60 s groups. For nerves exposed to longer durations of cryoanalgesia, the time taken for complete recovery was proportionally increased. Clinically, there was a statistically significant ($P < 0.05$) improvement in postoperative pain scores and use of opiate analgesia and an improvement ($P > 0.05$) in respiratory function tests for patients in the cryoanalgesia group. The previously suggested cutaneous sensory changes resolved within 6 months with complete restoration of function. **Conclusions**: We suggest that cryoanalgesia be considered as a simple, inexpensive, long-term form of post-thoracotomy pain relief, which does not cause any long-term histological damage to intercostal nerves. © 2001 Elsevier Science B.V. All rights reserved.

Keywords: Cryoanalgesia; Histology; Analgesia; Post-thoracotomy pain; Intercostal nerve

1. Introduction

Thoracotomy is one of the most painful surgical incisions currently used [1,2]. In treating the postoperative pain, the balance between adequate analgesia and potential side effects has been difficult to achieve. The pain is caused by the interaction of several factors including incisional pain, interruption of muscular and ligamentous structures by the retractor used during the surgical procedure and pain of pleural irritation secondary to the presence of the chest tube [3]. This alters respiratory physiology and may result in sputum retention, atelectasis, chest infections and other postoperative complications. By providing adequate analgesia it is possible to improve respiratory function, allow compliance with intensive physiotherapy and prevent some of these complications [4].

However, the treatment of postoperative thoracotomy pain remains controversial. Conventional analgesia involves opiates administered through parenteral routes. This method, although relatively easily available, is not always completely effective and is associated with a number of side effects, including respiratory depression [4]. Epidural

☆ Presented at the 14th Annual Meeting of the European Association of Cardio-thoracic Surgery, Frankfurt, Germany, October 7–11, 2000.

* Corresponding author. Tel.: +44-1895-828558; fax: +44-1895-828528.

E-mail address: cryotherapy@rbh.nthames.nhs.uk (M.O. Maiwand).

1010-7940/01/$ - see front matter © 2001 Elsevier Science B.V. All rights reserved.
PII: S1010-7940(01)00815-6

Downloaded from https://academic.oup.com/ejcts/article/20/3/502/365088 by guest on 07 November 2020

Table 1
Duration of cryoanalgesia on intercostal nerves

Nerves	Duration of cryo (s)
3rd and 4th	30
5th and 6th	60
7th and 8th	90
9th and10th	120

analgesia is a commonly used form of post-thoracotomy pain control and although effective, often necessitates the use of urinary catheters and reduces postoperative mobility whilst the epidural is in situ. Other techniques include intercostal nerve blocks for immediate postoperative pain control.

Cryoanalgesia, localized freezing of the intercostal nerves, is able to offer both short- and longer-term analgesia. It is based on the application of a cryoprobe, which employs the Joule–Thomson effect, whereby carbon dioxide or nitrous oxide is released at high pressure (4000–6000 kPa) and allowed to expand rapidly within the bulb of the cryoprobe [5]. This causes cooling of the probe tip to temperatures of approximately −50 to −70°C. When applied to peripheral nerves, localized freezing induces changes consistent with a second-degree nerve lesion (axonotmesis) [6–8]. The effects of cryoanalgesia are directly related to the formation of intra- and extracellular ice crystals, which result in microvascular changes and alteration of cellular osmolality and permeability, causing cell damage and disruption of nerve conduction [9].

Previous studies have suggested varying results regarding the effectiveness of cryoanalgesia and associated long-term cutaneous sensory changes [10–15]. This study aims to look at the histological changes induced by the application of localized freezing to the intercostal nerves in an animal model and to evaluate the reversibility of nerve damage associated with cryoanalgesia. The analgesic effect of cryoanalgesia was also assessed in comparison with conventional analgesia by carrying out a prospective, randomized, clinical trial at the China Japan Friendship Hospital, Beijing, China, in collaboration with the Department of Cryoresearch, Harefield Hospital, UK.

2. Materials and methods

2.1. Experimental study

Six hybrid dogs, average weight 17 kg, four male and two female, were anaesthetized using 25 mg/kg of intravenous 5% sodium pentobarbitol. A standard thoracotomy was performed, without opening the pleural space, exposing the 3rd to 10th intercostal nerves bilaterally, using blunt and sharp dissection. The Maiwand cryoprobe, operated via the Spembly 140 Cryounit using CO_2 as the cryogen, was applied to each nerve for 30, 60, 90 or 120 s (Table 1) achieving a probe temperature of −50°C.

Identifying the different intercostal nerves using specific markers, a segment of each nerve distal to the cryolesion was biopsied at various intervals over the following 6 months (1st, 3rd, 7th and 14th day, 1st, 3rd and 6th month postoperatively). The neural tissue was examined histologically, using routine haematoxylin and eosin stains as well as special immunohistochemical techniques, which specifically identify the axons and myelin sheaths. During the postoperative period, one dog died of pneumothorax at day 2 and another died at day 21 of septicaemia.

2.2. Clinical study

Patients undergoing elective thoracotomy were considered for this study. Those taking non-steroidal anti-inflammatory drugs or opiates preoperatively, with chest wall deformities, or neurological conditions were excluded. The study included 200 patients, 144 male and 56 female, with a mean age of 52.3 years (range 18–73). The surgical procedure was explained to the patients and informed consent obtained, before randomly allocating them to group A, conventional analgesia or group B, cryoanalgesia. All patients received standard anaesthesia with one-lung ventilation via an endobronchial tube. A posterolateral incision was used to gain access to the thorax for a number of operations (Table 2). The same physiotherapy and nursing staff carried out all postoperative care.

The patients in the conventional analgesia group were prescribed parenteral and oral dolantin, an opiate, ad libitum and their requirements documented. For patients in the cryoanalgesia group, before closure of the thorax, the intercostal nerves (one at the level of the incision, one cranial and two caudal) were identified and exposed by peeling off the parietal pleura. The Maiwand cryoprobe (with CO_2 as the cooling agent) was placed on each nerve, under direct vision, and each nerve received a 60-s application at a temperature of about −50°C. The cryoprobe was operated from a Spembly 140 Cryounit, causing localized freezing at a point proximal to the origin of the collateral branch (Fig. 1). A 10-s thaw was allowed prior to the removal of the probe to prevent adhesion to the tissues. The chest was

Table 2
Surgical procedures

	Group A: conventional analgesia	Group B: cryoanalgesia
Pneumonectomy	5	3
Lobectomy	51	48
Inoperable	3	2
Pleurectomy	7	5
Oesophagectomy	34	42
Total	100	100

Downloaded from https://academic.oup.com/ejcts/article/20/3/502/365088 by guest on 07 November 2020

closed in routine fashion, with the intercostal drains placed within the anaesthetized area.

Postoperatively, the degree of chest pain, use of opiate analgesia, respiratory function and complications were recorded. Postoperative pain was assessed using the Visual Analogue Scale, which consists of a 10-cm line divided into ten units representing the patient's pain level (0 = no pain, 10 = worst pain imaginable). This was recorded for 7 days postoperatively and then at regular intervals after discharge. Further to this, the requirement of opiate analgesia, dolantin, for pain control was documented. This additional analgesia was not withheld from patients in either group.

The respiratory function tests, carried out preoperatively and on days 3, 5, 7, 10, 15, 20 and 30 postoperatively, included the measurement of forced vital capacity (FVC) and forced expiratory volume in 1 s (FEV_1) using a standard spirometer. The best of three daily-recorded measurements was used in the assessment. Any complications occurring in the postoperative period were also recorded.

Statistical significance ($P < 0.05$) was determined comparing the pain scores, use of opiate analgesia and respiratory function tests between the cryoanalgesia and control groups using repeated measures analysis of variance.

3. Results

3.1. Histological study

Following 1-min application of the cryoprobe, the immediate changes showed axonal degeneration, accumulation of oedema fluid and capillary stasis. The endoneurium, however, remained intact. After 1 week, the axonal swelling gradually resolved and there were signs of Schwann cell proliferation, associated with a lymphocytic and histiocytic infiltrate. Axonal segments had also reappeared in some nerve fibres, indicating partial recovery, which was progressive and complete by 1 month. With longer periods of cryoapplication, the immediate changes in the intercostal nerves were the same (Figs. 2 and 3). The time taken for complete recovery, however, was proportionately increased, in particular the time to enter the recovery phase. Thus, following a 2-min application of the cryoprobe, axonal

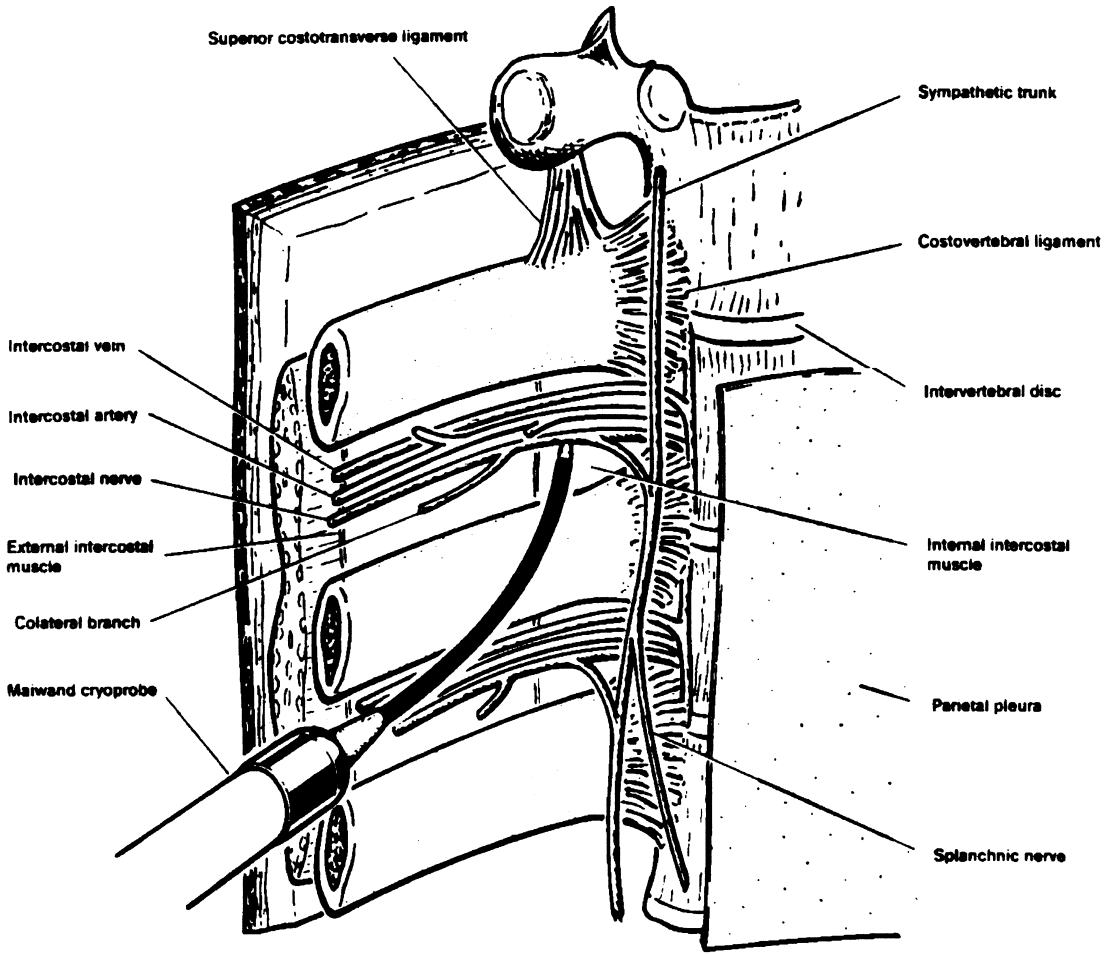

Fig. 1. Positioning of the probe.

Downloaded from https://academic.oup.com/ejcts/article/20/3/502/365088 by guest on 07 November 2020

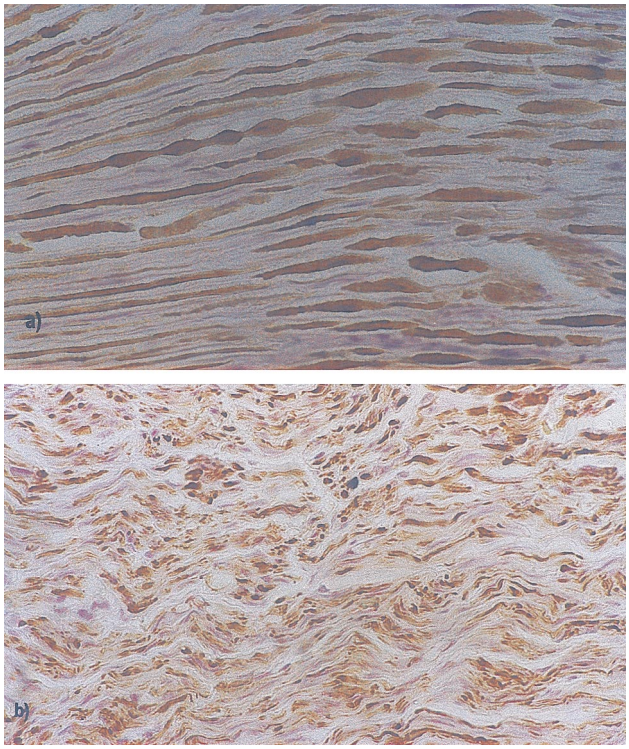

Fig. 2. Cryotherapy for 2 min: a longitudinal section of nerve stained by immunohistochemistry. (a) Day 1, showing axonal bleeding, swelling, disruption and severe degeneration. (b) One month; the nerve has almost completely recovered with most of the fibres fully regenerated axons. Magnification: 2.5 × 40.

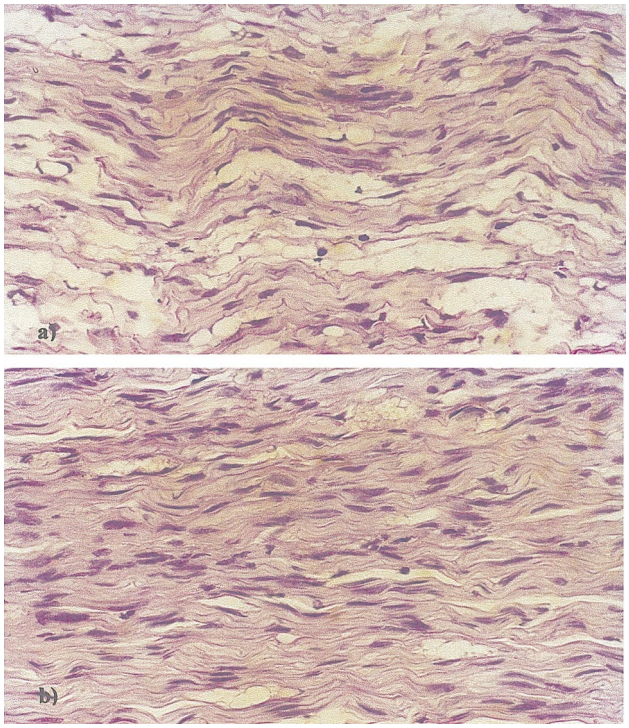

Fig. 3. Cryotherapy for 2 min: longitudinal section of nerve stained by hematoxylin and eosin. (a) Day 1; There is evidence of leukocytes, Schwann cell proliferation and residual oedema of axon. (b) One month; it is visible that there is almost a complete recovery of the nerve. Magnification: 2.5 × 40.

regeneration and resolution of the swelling only began at 2 weeks.

3.2. Clinical study

There was no statistical difference between the two groups with respect to age, gender, height or weight. Postoperative pain scores were significantly lower for patients in the cryoanalgesia group (Fig. 4). This was consistent the initial seven postoperative days for which the Visual Analogue Score was measured. Cryoanalgesia led to a significantly ($P < 0.05$) lower use of additional analgesia, dolantin, throughout the postoperative course (Fig. 5). As well as requiring a higher dose of opiate analgesia, patients in the control group required opiate analgesia for a longer period. When measuring respiratory function tests, it was noted that patients in the cryoanalgesia group achieved higher FEV_1 and FVC scores (Fig. 6), although this was not significant ($P > 0.05$).

3.3. Complications

There was one episode of respiratory failure in the conventional analgesia group and the patient subsequently died 1 week postoperatively. There were no episodes of wound infection in either group. Three patients in the control group had radiological and clinical evidence of atelectasis, which required vigorous physiotherapy for full lung expansion. There were no cases of atelectasis in the cryoanalgesia group. All of the patients in the cryoanalgesia group experienced numbness around the thoracotomy incision and the upper abdominal dermatomes for 1–3 months, and 11 patients experienced numbness for up to 6 months. Skin sensation returned to normal at 6 months for all patients.

4. Discussion

The use of cold as a form of analgesia has been around for

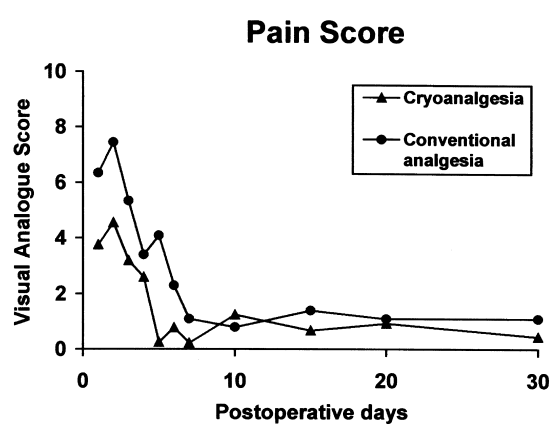

Fig. 4. Evolution of postoperative pain scores.

Downloaded from https://academic.oup.com/ejcts/article/20/3/502/365088 by guest on 07 November 2020

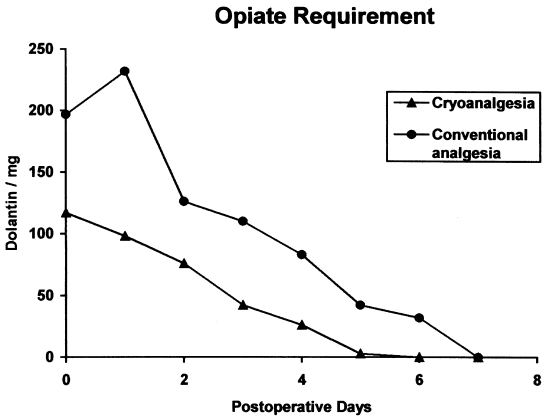

Fig. 5. Postoperative opiate requirements.

many years [16]. However, it was Lloyd [17] in 1976 who first introduced the concept of cryoanalgesia, whereby long-term pain relief could be achieved by the application of controlled localized freezing. He was able to treat pain both in the chronic (facial and back pain) and acute (post-thoracotomy) settings. The technique was further developed by Maiwand [18], who carried out a large number of clinical trials demonstrating the effectiveness of cryoanalgesia in the control of post-thoracotomy pain. The choice of post-thoracotomy analgesia, however, remains under debate.

The pain after thoracotomy can be very intense and can lead to severe postoperative complications. Several methods are currently employed to provide relief of post-thoracotomy pain. Each of the methods, however, is associated with specific disadvantages and side effects. Conventional analgesia usually focuses around parenteral opiate administration. It has been shown that this is not always effective and can be associated with many side effects including respiratory depression, nausea and vomiting, constipation and peripheral vasodilatation. Intercostal blocks are time consuming and often require repeated blocks. They also carry the risk of inducing pneumothorax and local anaesthetic toxicity. Continuous intercostal infusion, although avoiding the need for repeated blocks, increases the risk of toxicity. Epidural analgesia requires skilled anaesthetic technique and can induce hypotension, urinary retention and motor loss [13]. Alternative forms of long-term pain relief,

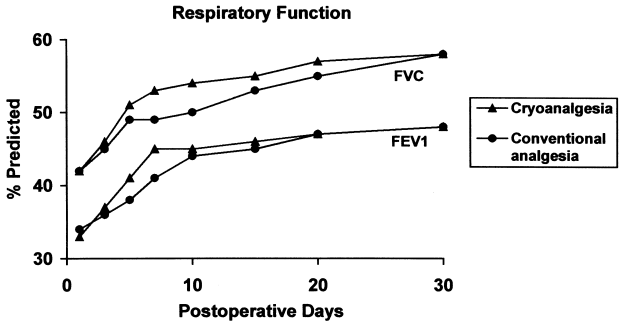

Fig. 6. Postoperative respiratory function.

including nerve section and phenol ablation, are no longer recommended due to the incidence of neuroma formation and permanent damage to the nerves [9,19].

Cryoanalgesia involves the delivery of a minimum temperature of −30°C via a probe to cause localized freezing of the nerve. This induces axonotmesis, which results in Wallerian degeneration of the axon and myelin sheath, distal to the lesion and occasionally a short distance proximal to the cryolesion [8]. Cryoanalgesia, having disrupted axonal continuity between the sensory nerve endings and the central nervous system, prevents the transmission of pain signals and hence provides a period of analgesia. As the remaining neural structures, including the perineurium and epineurium, consist of fibrous tissue, they can resist freezing damage. This allows regrowth of the nerve through the perineurial canal and maintains continuity with the end organ. Subsequent axonal regeneration is facilitated by this continuity and takes place at a rate of 1–3 mm/day [7]. The distance of the lesion from the end organ will determine when restoration of function will occur [20]. Our animal study confirms the presence of axonotmesis post cryoanalgesia and that repair and regeneration of the axon and myelin sheath was almost complete at 4 weeks. This suggests that cryoanalgesia does not induce any permanent neural damage.

Several studies have compared the use of cryoanalgesia against other forms of post-thoracotomy analgesia, with varying results [10–15]. Brichon et al. [15] showed that epidural analgesia provided faster and more effective analgesia and better restoration of pulmonary function. Similarly, Miguel and Hubbell [13] showed post-thoracotomy pain is best relieved with epidural analgesia compared with intrapleural analgesia, cryoanalgesia and parenteral morphine. Further to that, cryoanalgesia did not confer any advantage over intravenous morphine. Both Orr et al. and Pastor et al. [10,11], however, demonstrated a significant improvement in respiratory function and pain relief using a 60-s application of the cryoprobe in comparison to parenteral opiates. This study demonstrates the benefits of cryoanalgesia with respect to pain and respiratory function when compared to systemic opiates. It also confirms that the prolonged numbness and neuralgia suggested by previous studies [14] all resolved within 6 months, with restoration of normal sensation.

4.1. Study limitations

In the clinical component of this study, cryoanalgesia is compared against parenteral opiates as the standard form of analgesia in the control of post-thoracotomy pain. It is important to note that epidural and patient-controlled analgesia (PCA) are more commonly used in North America and Europe and provide an effective means of pain relief in this context. In China, however, where the clinical trial was carried out, access to and experience with epidural and PCA is not readily available and hence, cryoanalgesia is able to provide an alternative method of pain control. Another potential comment about the clinical study is that approxi-

Downloaded from https://academic.oup.com/ejcts/article/20/3/502/365088 by guest on 07 November 2020

mately one-third of the patients in both groups were operated for oesophagectomy and will therefore have undergone a thoraco-laparotomy. Although the extension of the incision over the abdominal cavity will affect respiratory function, the cryoanalgesia provided pain control for the laparotomy, as the 6th to 9th intercostal nerves were treated.

Cryoanalgesia, however, is not able to provide complete pain relief post-thoracotomy. Stretching of the dorsal spinal ligaments, which are supplied by the posterior spinal rami, generates a considerable amount of pain. Pain signals are also transmitted via the phrenic, vagi and sympathetic nerves as well as the intercostal nerves and hence not affected by the application of the cryoprobe. Cryoanalgesia is able to reduce postoperative analgesic requirement and facilitate control of post-thoracotomy pain. This improves respiratory function and hence reduces the incidence of any postoperative complications. This study suggests cryoanalgesia of the intercostal nerves be considered as an economical, safe and easy-to-use technique for the long-term control of post-thoracotomy pain.

Acknowledgements

The authors are grateful to Joanna Evans and Julia Beeson, Department of Cryoresearch, Harefield Hospital, for their help and dedication in preparing the manuscript.

References

[1] Loan WB, Dundee JW. Clinical assessment of pain. Practitioner 1967;198:759–768.
[2] Papper E, Brodie BB, Rovenstine EA. Postoperative pain: its use in the comparative evaluation of analgesics. Surgery 1952;32:107.
[3] Katz J. Cryoanalgesia for postthoracotomy pain. Ann Thorac Surg 1989;48:5.
[4] Simpson BR, Parkhouse J, Marshall R, Lambrechts W. Extradural analgesia and the prevention of postoperative respiratory complications. Br J Anaesth 1961;33:628–641.
[5] Evans PJD, Lloyd JW, Green CJ. Cryoanalgesia: the response to alterations in freeze cycle and temperature. Br J Anaesth 1981;53:1121–1127.
[6] Carter DC, Lee PWR, Gill W, Johnston RJ. The effect of cryosurgery on peripheral nerve function. J R Coll Surg Edinb 1972;17:25–31.
[7] Beazley RM, Bagley DH, Ketcham AS. The effects of cryosurgery on peripheral nerves. J Surg Res 1974;16:231–234.
[8] Denny-Brown D, Raymond D, Adams RD, Brenner C, Doherty MM. The pathology of injury to nerve induced by cold. J Neuropathol Exp Neurol 1945;4:305.
[9] Barnard D. The effect of extreme cold on sensory nerves. Ann R Coll Surg Engl 1980;62:180–187.
[10] Orr IA, Keenan DJM, Dundee JW. Improved pain relief after thoracotomy: use of cryoprobe and morphine infusion. Br Med J 1981;283:945-948.
[11] Pastor J, Morales P, Cases E, Cordero P, Piqueras A, Galàn G, Paris F. Evaluation of Intercostal cryoanalgesia versus conventional analgesia in postthoracotomy pain. Respiration 1996;63:241–245.
[12] Katz J, Nelson W, Forest R, Bruce DL. Cryoanalgesia for post-thoracotomy pain. Lancet 1980:512–513.
[13] Miguel R, Hubbell D. Pain management and spirometry following thoracotomy: a prospective randomised study of four techniques. J Cardiothorac Vasc Anesth 1993;7:529–534.
[14] Müller LC, Salzer GM, Ransamayr G, Neiss A. Intraoperative cryoanalgesia for postthoracotomy pain relief. Ann Thorac Surg 1989;48:15–18.
[15] Brichon PY, Pison C, Chaffanjon P, Fayot P, Burchberger, Neron L, Verdier J, Sarrazin. Comparison of epidural analgesia and cryoanalgesia in thoracic surgery. Eur J Cardio-thorac Surg 1994;8:482–486.
[16] Gage AA. History of cryosurgery. Semin Surg Oncol 1998;14:99–109.
[17] Lloyd JW, Barnard JDW, Glynn CJ. Cryoanalgesia: a new approach to pain relief. Lancet 1976;2:932–934.
[18] Maiwand MO, Makey AR, Rees A. Cryoanalgesia after thoracotomy. J Thorac Cardiovasc Surg 1986;92:291–295.
[19] Gaster RN, Davidson TM, Rand RW. Comparison of nerve regeneration rates following controlled freezing or crushing. Arch Surg 1971;103:378–383.
[20] Evans PJD. Cryoanalgesia. Anaesthesia 1981;36:1003–1013.

Appendix A. Conference discussion

Dr H.-B. Ris (*Lausanne, Switzerland*): You used conventional anesthesia based on morphine derivatives, but most centres use actually continuous peridural analgesia. Could you comment on that please?

Dr Maiwand: The work was completed at Beijing University; the comparison you mentioned has not been done.

Dr Ris: Have you looked at the long-term results after cryoanalgesia regarding post-thoracotomy pain? How do these patients do several months after the operation since you have shown substantial damage to these nerves occurring after cryoanalgesia?

Dr Maiwand: We have studied the effect of cryoanalgesia for a year and have published the results in the American Cardio-thoracic Journal; we reported a main weakness of the anterior chest wall, based on our suggestion that cryoanalgesia must not be used on young patients, especially females, to prevent numbness of the nerves covering the breast area. Histological examination shows regeneration of nerves occurs within a month and long-term examination of histology has shown no nerve damage.

Dr K. Al Kattan (*Riyadh, Saudi Arabia*): We have been using cryo for some time now, probably 15 years, and the thing that we noted in addition to the transient numbness is actually atrophy of the breast. We had one case who was pregnant and she noted a difference during lactation. So we stopped doing it for the young female patient.

Dr Maiwand: I think years ago I made that point, and I have written and I have published it, that it must not be used for the young female. I fully agree with you. Atrophy is the lack of conduction of the nerve for a length of time. That length of time is enough so that the muscle becomes smaller. But you do recover. I think the good point is that histologically it has been proven that regeneration of the nerve is there.

Dr K. Moghissi (*Yorkshire Laser Centre, UK*): After cryoanalgesia, would you get the different type of pain sensation, causalgia, that you get after neurectomy?

Dr Maiwand: I agree with you. I think you are absolutely right. Sensitivity of the skin is much higher. You are more sort of sensitive when touched. You might not have feeling, but it is sort of a disturbing sensation. But I think at the end of the day, what we are talking about is to reduce the complications, and with this type of patient, you know that they will go through complications. I think it's well worth it to do it on this group of patients with an extended thoracotomy incision, a long length of thoracotomy, and also you know with poor respiratory function that you will have a problem later on with sputum retention. As I said, there isn't a method that we could all say is the best, but on balance, in a group of patients that you could choose, I have a feeling that it is still one of the best. American colleagues who use cryoanalgesia send their patients home quickly. It does have that good point, as well as the bad point that we have discussed.

Downloaded from https://academic.oup.com/ejcts/article/20/3/502/365088 by guest on 07 November 2020